



# Laryngeal Manifestations of Systemic Diseases







# Laryngeal Manifestations of Systemic Diseases

**Abdul-Latif Hamdan, MD, EMBA, MPH, FACS**  
**Robert Thayer Sataloff, MD, DMA, FACS**  
**Mary J. Hawkshaw, BSN, RN, CORLN**





5521 Ruffin Road  
San Diego, CA 92123

e-mail: [information@pluralpublishing.com](mailto:information@pluralpublishing.com)  
Website: <http://www.pluralpublishing.com>

Copyright © 2019 by Plural Publishing, Inc.

Typeset in 10/12 Palatino by Achorn International  
Printed in the United States of America by Integrated Books International

All rights, including that of translation, reserved. No part of this publication may be reproduced, stored in a retrieval system, or transmitted in any form or by any means, electronic, mechanical, recording, or otherwise, including photocopying, recording, taping, Web distribution, or information storage and retrieval systems without the prior written consent of the publisher.

For permission to use material from this text, contact us by  
Telephone: (866) 758-7251  
Fax: (888) 758-7255  
e-mail: [permissions@pluralpublishing.com](mailto:permissions@pluralpublishing.com)

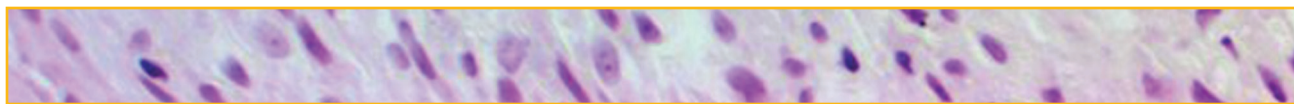*Every attempt has been made to contact the copyright holders for material originally printed in another source. If any have been inadvertently overlooked, the publishers will gladly make the necessary arrangements at the first opportunity.*

#### NOTICE TO THE READER

Care has been taken to confirm the accuracy of the indications, procedures, drug dosages, and diagnosis and remediation protocols presented in this book and to ensure that they conform to the practices of the general medical and health services communities. However, the authors, editors, and publisher are not responsible for errors or omissions or for any consequences from application of the information in this book and make no warranty, expressed or implied, with respect to the currency, completeness, or accuracy of the contents of the publication. The diagnostic and remediation protocols and the medications described do not necessarily have specific approval by the Food and Drug administration for use in the disorders and/or diseases and dosages for which they are recommended. Application of this information in a particular situation remains the professional responsibility of the practitioner. Because standards of practice and usage change, it is the responsibility of the practitioner to keep abreast of revised recommendations, dosages, and procedures.

#### Library of Congress Cataloging-in-Publication Data:

Names: Hamdan, A. L. (Abdul Latif), editor. | Sataloff, Robert Thayer, editor. | Hawkshaw, Mary, editor. |  
Based on (work): Sataloff, Robert Thayer. Professional voice. Fourth edition.  
Title: Laryngeal manifestations of systemic diseases / [edited by] Abdul-Latif Hamdan, Robert Thayer Sataloff, Mary J. Hawkshaw.  
Description: San Diego, CA : Plural Publishing, [2019] | "Some of the material in this book was derived from Sataloff, RT. Professional Voice: The Science and Art of Clinical Care, Fourth Edition. San Diego, California: Plural Publishing, Inc.; 2017 . . . much of the material in Laryngeal Manifestations of Systemic Disease is new, reworked, and/or expanded"—Pref. | Includes bibliographical references and index.  
Identifiers: LCCN 2018028889 | ISBN 9781635501292 (alk. paper) | ISBN 1635501296 (alk. paper)  
Subjects: | MESH: Voice Disorders—physiopathology | Voice—physiology | Larynx—pathology  
Classification: LCC RF510 | NLM WV 500 | DDC 616.85/506—dc23  
LC record available at <https://lcn.loc.gov/2018028889>



# Contents

Preface		vii
Contributors		ix
Chapter 1	Clinical Anatomy and Physiology of the Voice <i>Robert Thayer Sataloff</i>	1
Chapter 2	Genetics of the Voice <i>Robert Thayer Sataloff and Mary J. Hawkshaw</i>	41
Chapter 3	Impact of Aging on the Voice <i>Abdul-Latif Hamdan, Robert Thayer Sataloff, and Mary J. Hawkshaw</i>	49
Chapter 4	Common Medical Diagnoses and Treatments in Patients with Voice Disorders: An Introduction and Overview <i>Robert Thayer Sataloff, Mary J. Hawkshaw, and Johnathan B. Sataloff</i>	59
Chapter 5	Sleep, Body Fatigue, and Voice <i>Abdul-Latif Hamdan, Robert Thayer Sataloff, and Mary J. Hawkshaw</i>	83
Chapter 6	Laryngeal Manifestations of Neurologic Disorders <i>Abdul-Latif Hamdan, Robert Thayer Sataloff, and Mary J. Hawkshaw</i>	87
Chapter 7	Psychological Aspects of Voice Disorders <i>Deborah Caputo Rosen, Reinhardt J. Heuer, David A. Sasso, and Robert Thayer Sataloff</i>	119
Chapter 8	Impact of the Auditory System on Voice <i>Morgan A. Selleck and Robert Thayer Sataloff</i>	151
Chapter 9	Laryngeal Manifestations of Respiratory Disorders <i>Abdul-Latif Hamdan, Robert Thayer Sataloff, and Mary J. Hawkshaw</i>	159
Chapter 10	Allergy <i>John R. Cohn, Patricia A. Padams, Mary J. Hawkshaw, and Robert Thayer Sataloff</i>	183
Chapter 11	Laryngeal Manifestations of Gastrointestinal Disorders <i>Robert Thayer Sataloff, Donald O. Castell, Philip O. Katz, Dahlia M. Sataloff, and Mary J. Hawkshaw</i>	189
Chapter 12	Laryngeal Manifestations of Autoimmune Diseases <i>Abdul-Latif Hamdan, Robert Thayer Sataloff, and Mary J. Hawkshaw</i>	281
Chapter 13	Laryngeal Manifestations of Endocrine Disorders <i>Abdul-Latif Hamdan, Robert Thayer Sataloff, and Mary J. Hawkshaw</i>	313





vi

LARYNGEAL MANIFESTATIONS OF SYSTEMIC DISEASES

Chapter 14	Bodily Injuries and Their Effects on the Voice <i>Robert Thayer Sataloff</i>	341
Chapter 15	Medications and the Voice <i>Robert Thayer Sataloff, Mary J. Hawkshaw, Joseph Anticaglia, Michelle White, Kirsten Meenan, and Jonathan J. Romak</i>	345
Index		375



## Preface

Voice conveys much more than intellectual messages. Most people recognize vocal expression of emotion. For example, when we answer a phone call from a parent, we need to hear no more than the word “hello” to know whether the call brings good news or bad. Similarly, voice change may offer the first indication of various systemic disorders. *Laryngeal Manifestations of Systemic Disease* summarizes the vocal changes that occur with disorders throughout the body. It is common for dysphonia to be the first manifestation of systemic disease. So, familiarity with laryngeal manifestation of systemic disease is important not only for otolaryngologists and phoniatriests, but also for family practitioners, internists, medical students, physician assistants, nurse practitioners, nurse clinicians, speech-language pathologists, singing voice specialists, acting voice specialists, voice teachers, and others entrusted with the care, education, and health of the human voice. This book is intended for all such professionals, and for patients, particularly professional voice users, who want to know as much as possible about their instrument and conditions that might affect it adversely.

*Laryngeal Manifestations of Systemic Disease* synthesizes current knowledge about voice modifications associated with various disorders.

After providing basic introductory information in the initial chapters, the chapters in this book review pathophysiology of systemic diseases and their effects on phonation, with summaries of current literature; and we have attempted to assist clinicians by including intriguing cases and images. Some of the material in this book was derived from R.T. Sataloff *Professional Voice: The Science and Art of Clinical Care, Fourth Edition* (2017), San Diego, California: Plural Publishing, Inc., with the permission of Plural Publishing, Inc. However, although that publication is recent, much of the material in *Laryngeal Manifestations of Systemic Disease* is new, reworked, and/or expanded.

Chapter 1, Clinical Anatomy and Physiology of the Voice, contains a great deal of information about laryngeal anatomy, neuroanatomy, respiratory function and other topics that, to the best of our knowledge, has not been synthesized in similar detail in a

single source elsewhere, except in Sataloff's *Professional Voice: The Science and Art of Clinical Care, Fourth Edition*, from which this chapter has been republished. Chapter 2 on Genetics of the Voice reviews what is known about the genetics of voice from a clinical perspective. Genetic considerations are increasingly important to understanding and treating systemic disease. In Chapter 3 on the Impact of Aging on the Voice, we summarize vocal changes associated with the aging process, a common and expected cause of voice modification. Chapter 4, Common Medical Diagnoses and Treatments in Patients with Voice Disorders: An Introduction and Overview, provides insights on a great many maladies that may alter the voice, some of which are covered in much greater details in subsequent chapters. Chapter 5 on Sleep, Body Fatigue, and Voice reviews the importance of sleep and general well-being to vocal health, and dysphonic changes that might be expected with deficiencies in either. Laryngeal Manifestations of Neurologic Disorders are discussed in Chapter 6. In this chapter, various neurological conditions are summarized including tremor, multiple sclerosis, myasthenia gravis, dystonia, and others. Understanding the pathophysiology of their effects on voice should be of value to anyone caring for the many patients with such maladies. In addition to covering various aspects of psychological assessment and treatment, Chapter 7 on Psychological Aspects of Voice Disorders integrates information on the role of psychological professionals and others involved in management of emotional and psychological challenges in voice patients. Chapter 8, Impact of the Auditory System on Voice, reviews dysphonia associated with hearing function and dysfunction. Laryngeal Manifestations of Respiratory Disorders, Chapter 9, reviews the many effects of respiratory dysfunction upon phonation. Since “support,” or the power source of the voice, depends upon efficient pulmonary function and aerobic conditioning, respiratory disorders commonly are associated with dysphonia. Allergies often cause dysphonia, and basic, clinically practical information on this topic is presented in Chapter 10. In Chapter 11 on Laryngeal Manifestations of Gastrointestinal Disorders, the impact of gastroenterological

dysfunction upon phonation is reviewed in detail, with special attention to laryngopharyngeal reflux. This chapter includes approximately 600 references in a comprehensive update of this important topic and it is republished from the fourth edition of Sataloff's book on Professional Voice. Laryngeal Manifestations of Autoimmune Disorders, Chapter 12, reviews many of the autoimmune diseases that may affect the voice including rheumatoid arthritis, systemic lupus erythematosus, and others. Chapter 13, Laryngeal Manifestations of Endocrine Disorders, provides an overview of endocrinologic dysfunction. The voice is extremely sensitive to even slight changes in the hormonal environment, and good laryngologists commonly diagnose endocrinologic disorders based on a presenting complaint of dysphonia. Chapter 14 on

Bodily Injuries and Their Effects on the Voice, presents the consequences of trauma upon phonation. Any injury that causes pain (back, neck, extremity, shoulder, or elsewhere) that alters posture or muscle function and balance may affect the voice. Chapter 15 on Medications and the Voice reviews the voice effects associated with many medications commonly prescribed for disorders throughout the body. Not only systemic disease but also its treatment may be responsible for a voice complaint.

We hope that this book will prove useful for our readers and will help make all of us better holistic diagnosticians. When a patient presents with a voice complaint and we diagnose a previously unrecognized systemic disease, we may not only improve the voice, but we also may save a life.

—Abdul-Latif Hamdan, MD, EMBA, MPH, FACS,  
American University of Beirut Medical Center

—Robert T. Sataloff, MD, DMA, FACS,  
Drexel University College of Medicine

—Mary J. Hawkshaw, RN, BSN, CORLN,  
Drexel University College of Medicine





## Contributors

**Joseph Anticaglia, MD**

Ear, Nose, and Throat Associates of New York  
Flushing, New York  
*Chapter 15*

**Donald O. Castell, MD**

Professor of Medicine  
Director of Esophageal Disorders Program  
Department of Gastroenterology and Hepatology  
Charleston, South Carolina  
*Chapter 11*

**John R. Cohn, MD, FCCP**

Professor of Medicine and Pediatrics  
Thomas Jefferson University  
Philadelphia, Pennsylvania  
*Chapter 10*

**Abdul-Latif Hamdan, MD, EMBA, MPH, FACS**

Professor of Otolaryngology, Head and Neck  
Surgery  
Head, Division of Laryngology  
Director of "Hamdan Voice Unit"  
American University of Beirut Medical Center  
Beirut, Lebanon  
*Chapters 3, 5, 6, 9, 12, 13*

**Mary J. Hawkshaw, RN, BSN, CORLN**

Research Professor  
Department of Otolaryngology-Head and Neck  
Surgery  
Drexel University College of Medicine  
Philadelphia, Pennsylvania  
*Chapters 2, 3, 4, 5, 6, 9, 10, 11, 12, 13, 15*

**Reinhardt J. Heuer, PhD**

Professor Emeritus  
Department of Communication Sciences and  
Disorders  
Temple University  
Adjunct Professor  
Department of Otolaryngology-Head and Neck  
Surgery  
Drexel University College of Medicine  
Philadelphia, Pennsylvania  
*Chapter 7*

**Philip O. Katz, MD**

Professor  
Department of Medicine  
Division of Gastroenterology  
Weill Cornell Medical Center  
New York, New York  
*Chapter 11*

**Kirsten Meenan, BS**

Drexel University College of Medicine  
Philadelphia, Pennsylvania  
*Chapter 15*

**Patricia A. Padams, RN, BSN, CEN**

Nurse Manager and Clinical Research Coordinator  
(In association with John R. Cohn, MD)  
Thomas Jefferson University  
Philadelphia, Pennsylvania  
*Chapter 10*

**Jonathan J. Romak, MD**

Instructor  
Department of Otolaryngology-Head and Neck  
Surgery  
Drexel University College of Medicine  
Philadelphia, Pennsylvania  
*Chapter 15*

**Deborah Caputo Rosen, RN, PhD**

President  
Caputo Rosen Consulting  
Philadelphia, Pennsylvania  
*Chapter 7*

**David A. Sasso, MD, MPH**

Assistant Clinical Professor  
Child Study Center  
Yale School of Medicine  
New Haven, Connecticut  
*Chapter 7*

**Dahlia M. Sataloff, MD**

Chairman, Department of Surgery  
Pennsylvania Hospital  
Professor of Clinical Surgery  
University of Pennsylvania

Perelman School of Medicine  
Philadelphia, Pennsylvania  
*Chapter 11*

**Johnathan B. Sataloff, BS, BA**  
Harvard Medical School  
Harvard University  
Boston, MA  
*Chapter 4*

**Robert Thayer Sataloff, MD, DMA, FACS**  
Professor and Chairman  
Department of Otolaryngology-Head and Neck  
Surgery  
Senior Associate Dean for Clinical Academic  
Specialties  
Drexel University College of Medicine  
Chairman, The Voice Foundation  
Chairman, American Institute for Voice and Ear  
Research

Faculty, Academy of Vocal Arts  
Philadelphia, Pennsylvania  
*Chapters 1, 2, 3, 4, 5, 6, 7, 8, 9, 10, 11, 12, 13, 14, 15*

**Morgan A. Selleck, MD**  
Resident  
Department of Otolaryngology-Head and Neck  
Surgery  
Chapel Hill School of Medicine  
University of North Carolina  
Chapel Hill, North Carolina  
*Chapter 8*

**Michelle White, BA**  
Drexel University College of Medicine  
Philadelphia, Pennsylvania  
*Chapter 15*



# 1

## Clinical Anatomy and Physiology of the Voice

*Robert Thayer Sataloff*

### Anatomy

The anatomy of the voice is not limited to the region between the suprasternal notch and the hyoid bone. Practically all body systems affect the voice. The larynx receives the greatest attention because it is the most sensitive and expressive component of the vocal mechanism, but anatomic interactions throughout the patient's body must be considered in treating voice disorders. It is helpful to think of the larynx as composed of 4 anatomic units—skeleton, mucosa, intrinsic muscles, and extrinsic muscles—as well as vascular, neurological, and other related structures. The glottis is the space between the vocal folds. The term *vocal cords* was abandoned in favor of the term *vocal folds* more than 3 decades ago. Vocal folds is a more accurate description of the structure, as described below (although not quite so accurate as the German term “vocal lips”). Moreover, the word “cord” often makes people think of a string-like structure, and vocal fold motion is not similar to a vibrating string.

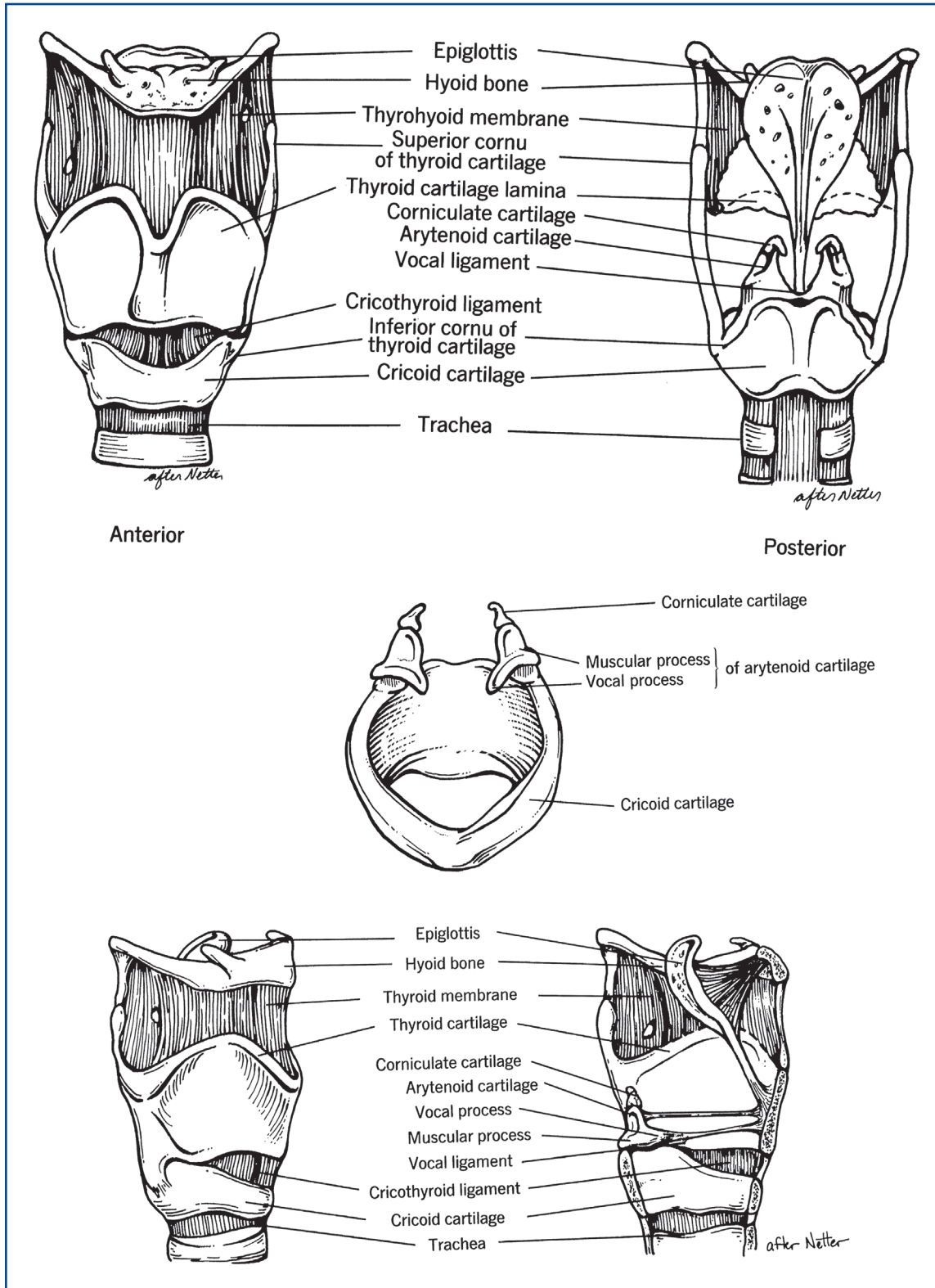
#### Laryngeal Skeleton: Cartilages, Ligaments, and Membranes

The most important parts of the laryngeal skeleton are the thyroid cartilage, the cricoid cartilage, and the 2 arytenoid cartilages (Figure 1–1). The laryngeal cartilages are connected by soft attachments that allow changes in their relative angles and distances, thereby permitting alterations in the shape and tension of the tissues extended between them. The intrinsic muscles of the larynx are connected to these cartilages.

For example, one of the intrinsic muscles, the thyroarytenoid (TA), extends on each side from the arytenoid cartilage to the inside of the thyroid cartilage just below and behind the thyroid prominence. The medial belly of the TA is also known as the vocalis muscle, and it forms the body of the vocal fold.

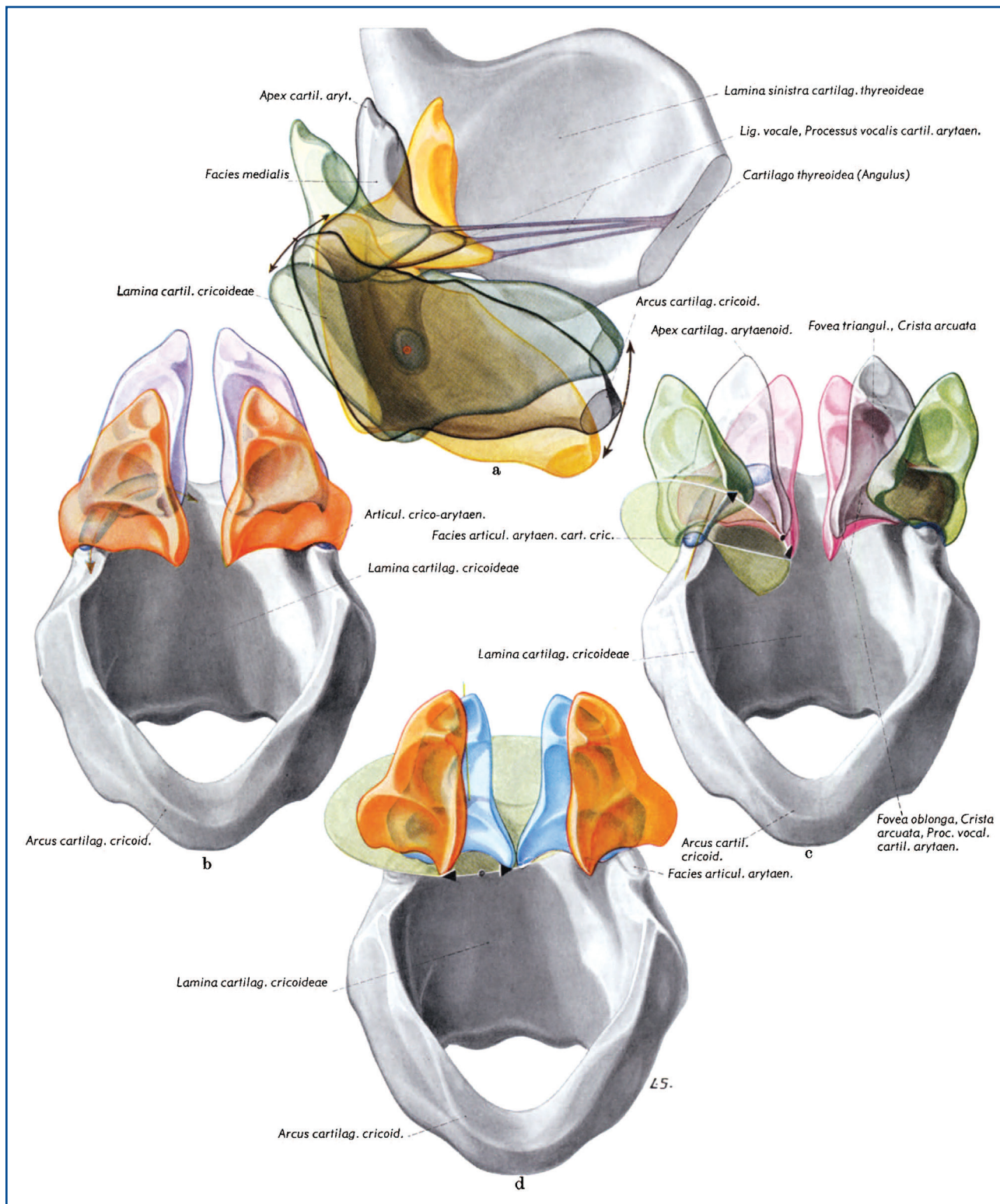
The pyramidal, paired arytenoid cartilages sit atop the superior edge of the cricoid cartilage. They each include a muscular process, a vocal process and an apex, a body, and a complex, concave articular surface. They are hyaline cartilages, except for the vocal process, and the apices in some cases, which are composed of fibroelastic cartilage. The hyaline portions generally begin to ossify at around 30 years of age.<sup>2</sup> Clinically, arytenoid asymmetry is common. Hamdan et al. studied 110 singers (male-to-female ratio of 2:1) and found no correlation between arytenoid asymmetry and vocal symptoms.<sup>3</sup> In a later study, they also found no correlation between arytenoid asymmetry and posture, neck tension, or glottal attack.<sup>4</sup> Bonilha et al also found that arytenoid asymmetry was common, but there were no statistically significant differences in prevalence of arytenoid asymmetries comparing subjects with normal voices and those with dysphonia.<sup>5</sup>

Ossification of the thyroid cartilage begins earlier, usually at around 20 years of age, and usually begins posteriorly and inferiorly.<sup>2</sup> The 2 thyroid laminae join in the midline, forming an angle of approximately 120° in women and approximately 90° in men. The thyroid prominence is also more noticeable in men and is commonly known as the “Adam’s apple.” Just above the thyroid prominence, the thyroid laminae form a “V,” the thyroid notch. Posteriorly, the



A

Figure 1-1. A. Cartilages of the larynx. (continues)



**B**

**Figure 1-1.** (continued) **B.** Schematic representation of position changes of laryngeal cartilages illustrating the most extreme positions achieved by each. (Reproduced with permission from Pernkopf.<sup>1</sup>)

laminae extend to form superior and inferior cornua (horns). The superior cornu connects to the hyoid bone via the thyrohyoid ligament. The inferior cornu is connected to the cricoid cartilage by a synovial cricothyroid joint. The joint is encased in a capsular ligament, which is strengthened posteriorly by a fibrous band. Movement of the paired cricothyroid joints is diarthrodial. The primary movement is rotary, with the cricoid rotating around a transverse axis passing through both joints. Gliding in various directions also occurs to a limited extent. This joint tends to move anteromedially during vocal fold adduction and posterolaterally during vocal fold abduction and permits the anterior aspects of the cricoid and thyroid cartilages to be brought more closely together to increase vocal fold length (and frequency of phonation, or pitch) in response to cricothyroid (CT) muscle contraction.

The perichondrium of the thyroid cartilage is thinner internally than externally. Externally, in the midline, there is a tiny landmark that can be helpful in identifying the position of the anterior commissure.<sup>6</sup> This small, diamond-shaped surface depression is associated with a slightly lighter color compared to the adjacent thyroid cartilage. It is found in the anterior midline, approximately halfway between the thyroid notch and the inferior border of the thyroid cartilage, and a small, unnamed artery travels through this tiny depression, as described by Adams et al.<sup>6</sup> The landmark is referred to sometimes as Montgomery's aperture. At a corresponding location on the inner surface, there is a small protrusion that is devoid of perichondrium. This is the point of attachment of Broyles ligament and the anterior commissure tendon. The rest of the thyroid cartilage is covered with fairly thick perichondrium, and the smooth, concave inner surface is covered by a mucosal membrane. Broyles ligament is formed by the vocal ligament (which is also the upper border of the conus elasticus), the internal perichondrium of the thyroid cartilage, and the thyroepiglottic ligament.

The oblique line is another important external landmark of the thyroid cartilage. It runs anteroinferiorly from a superior thyroid tubercle located just inferior to the superior cornu, and it extends to the inferior thyroid tubercle located at the lower border of the thyroid lamina. The oblique line is actually a ridge to which the thyrohyoid, sternothyroid, and inferior pharyngeal constrictor muscles attach. Fibers from the palatopharyngeus and stylopharyngeus muscles attach to the posterior border of the thyroid cartilage.

The signet ring-shaped cricoid cartilage is the only circumferential cartilaginous structure in the airway. Its posterior lamina may rise to a height of approximately 30 millimeters (mm), and its anterior arch

may be only a few millimeters in height. Not only is the anterior aspect of the arch thin, but it also ossifies later than the posterior aspect of the cricoid cartilage, which begins to ossify in the early to mid-20s. Because the anterior portion of the arch is both thin and tends to ossify later, it is particularly prone to fracture during surgical manipulation. This should be remembered in procedures such as cricothyroid approximation; traction should always be centered laterally on the cricoid arch, rather than near the midline. The cricoid and thyroid cartilages are joined through the cricothyroid joints. These synovial joints vary among individuals. They have been divided into 3 groups.<sup>7</sup> In group 1, the rotation axis of the cricothyroid joint is located in the lower third of the joint (13 of 24 specimens studied); in group 2, it is located in the middle third of the joint (5/23); and in group 3 the effective axis of rotation is located in the lower third of the cricoid cartilage. Elongations of the vocal fold were 12% in group 1, 8% in group 2, and 3% in group 3. These differences may be important for patients undergoing cricothyroid approximation surgery, but more research is needed to confirm these findings and investigate their clinical implications. The cricoid is connected to the thyroid cartilage not only through the cricothyroid joints, but also through the cricothyroid membrane and its midline thickening known as the cricothyroid ligament.

Internal dimensions of the cricoid cartilage and trachea vary substantially. Such information is important with regard to tracheal intubation, dilatation, stenting, endoscopy, anastomosis, and transplantation. The luminal cross sections vary between and among men and women. The smallest dimension occurs in the frontal plane.<sup>8</sup> In women, this measures approximately 11.6 mm, with a range of 8.9 to 17 mm. In men, it is about 15 mm, with a range of 11 to 21.5 mm. The distance between the cricoarytenoid joint facets varies from person to person, as well, as does the angle between longitudinal axes of the cricoarytenoid joint facets (42°–74° in women, 37°–75° in men).<sup>8</sup> Morphometric characteristics of the larynx have also been studied by Jotz et al.<sup>9</sup> They examined larynges of 50 male and 50 female fresh cadavers of humans older than 40 years. All laryngeal measurements were greater in men than in women except for the thyroid angle that was greater in women. There was no significant difference in morphological comparison between men and women among various age groups.

The cross section of the trachea is also highly variable, with a frontal diameter reported as narrow as 9.9 mm in women and 12 mm in men.<sup>8</sup> The marked variation in size and shape highlights the difficulty in creating a standardized rigid stent. It should also

be noted that the diameter of the cricoid ring in some women is too narrow to permit the atraumatic passage of an endotracheal tube with a 7-mm internal diameter. Anatomic variation also must be taken into consideration during laryngotracheal replacement or transplantation.

In addition to the cricoid, thyroid, and paired arytenoid cartilages, there are numerous other components of the laryngeal skeleton and the related structures. The superior aspect of the laryngeal skeleton is the hyoid bone, which is usually ossified by age 2. The hyoid bone attaches to the mylohyoid, geniohyoid, and hyoglossus muscles superiorly and inferiorly connects to the thyroid cartilage via the thyrohyoid membrane. This U-shaped bone has an inferiorly located lesser cornu and a superiorly located greater cornu on each side.

The epiglottis is a fibroelastic cartilage that is shaped like a leaf and narrows inferiorly where it becomes the petiole. The petiole attaches to the inner surface of the thyroid cartilage immediately below the thyroid notch by the thyroepiglottic ligament. The superior aspect of the epiglottis faces the base of the tongue anteriorly and the laryngeal inlet posteriorly. The hyoepiglottic ligament connects the posterior surface of the hyoid bone to the lingual surface of the epiglottis. On its laryngeal surface, the epiglottis contains a protuberance that sometimes obscures view of the anterior commissure. This is the epiglottic tubercle. Perichondrium is less densely adherent to the epiglottic cartilage on the lingual surface than on the laryngeal surface, explaining why epiglottic edema tends to be more prominent in the vallecula than in the laryngeal inlet. However, edema on the lingual surface can push the epiglottis posteriorly, resulting in airway obstruction. The preepiglottic space is formed by the mucosa of the vallecula superiorly, the thyroid cartilage and thyrohyoid membrane anteriorly, and the epiglottis posteriorly and inferiorly. Blood vessels and lymphatic channels course through this space.

There are several cartilages of less functional importance located above the thyroid cartilage. The cartilages of Santorini, or corniculate cartilages, are fibroelastic and are found above the arytenoid cartilages. They help improve the rigidity of the aryepiglottic folds. Like the epiglottis and many other elastic cartilages, they do not ossify. The cuneiform cartilages (cartilages of Wrisberg) also do not ossify, even though they consist of hyaline cartilage. They are located in the aryepiglottic folds and also improve rigidity, helping to direct swallowing toward the piriform sinuses. The triticeal cartilages are located laterally within the thyrohyoid ligaments. These structures are hyaline cartilages and often do ossify

(as may the lateral thyrohyoid ligaments themselves). They may easily be mistaken on x-rays for foreign bodies. The lateral thyrohyoid ligaments are actually thickenings of the thyrohyoid membrane. There is also more central thickening called the medial thyrohyoid ligament. The laryngeal vessels and the internal branches of the superior laryngeal nerves enter the thyrohyoid membrane posterior to the lateral thyrohyoid ligaments. The thyrohyoid ligaments and membranes are among the structures that suspend the larynx directly or indirectly from the skull base. The other structures that do so include the stylohyoid ligaments, the thyrohyoid ligaments and membrane, the thyroepiglottic ligaments, the cricothyroid ligaments and membrane, the cricoarytenoid ligaments, and the cricotracheal ligament and membrane.

The arytenoid cartilages are capable of complex motion. Previously, it was believed that the arytenoids rock, glide, and rotate. More accurately, the cartilages are brought together in the midline and revolve over the cricoid. It appears as if individuals use different strategies for approximating the arytenoids, and these strategies may influence a person's susceptibility to laryngeal trauma that can cause vocal process ulcers and laryngeal granulomas.

The larynx contains 2 important, large, paired "membranes," the triangular membranes and the quadrangular membranes (Figure 1–2). The paired triangular membranes form the conus elasticus. Each triangular membrane is attached to the cricoid and thyroid cartilages anteriorly (the base of the triangular membrane), to the cricoid cartilage inferiorly, and to the vocal process of the arytenoid cartilage posteriorly (the apex of the triangular membrane). The superior edge of each fibroelastic triangular membrane is the vocal ligament, forming the intermediate and deep layers of lamina propria of the vocal folds, as discussed below. These structures extend anteriorly to form a portion of Broyles ligament. More anteriorly, a portion of the conus elasticus constitutes the cricothyroid ligament.

Like the upper border of the triangular membrane, the upper and lower borders of the quadrangular membrane are free edges. The upper border of each quadrangular membrane is the aryepiglottic fold, bilaterally. The lower border extends from the inferior aspect of the epiglottis to the vocal process of the arytenoid cartilages and forms part of the vestibular (or ventricular) fold, or false vocal fold. Superior and inferior thickenings in the quadrangular membrane form the aryepiglottic ligament and the vestibular ligament, respectively. The quadrangular membrane is shorter in vertical height posteriorly than anteriorly. Lateral to these structures is a region called the paraglottic space. It is bounded laterally by the thyroid